

Layers of Neuroscience

Serge O. Dumoulin^{1,2,3,*}

¹Spinoza Centre for Neuroimaging, 1105BK Amsterdam, Netherlands

²Experimental Psychology, Utrecht University, 3584CS Utrecht, Netherlands

³Experimental and Applied Psychology, VU University Amsterdam, 1081BT Amsterdam, Netherlands

*Correspondence: s.dumoulin@spinozacenter.nl

<https://doi.org/10.1016/j.neuron.2017.12.004>

In a patch of cortex, laminae connect to different parts of the brain. Huber et al. (2017) demonstrate the ability of human neuroimaging to derive laminar information flow between brain regions, paving the way for human neuroscience applications.

The cortex consists of six layers or laminae. These laminae were the first distinguishable structure of the cortex, and differences in laminae formed the foundation to identify distinct cortical areas (Brodmann, 1903).

Cortical laminae differ in neuronal content but also in their connectivity to other parts of the brain. The relative sizes of laminae vary across the cortex in line with their functions and connectivity. For example, thalamocortical connections arrive primarily in central (granular) layers. The granular layer is most prominent in primary sensory cortices and nearly absent in motor cortex. Likewise, supra-granular layers are the primary origin and termination of corticocortical connections, whereas infragranular layers connect the cortex with subcortical and corticospinal regions (Figure 1). Thus, cortical laminae contain unique information on the information flow within the brain (Shipp, 2005).

Laminae are beyond the reach of conventional human neuroimaging, limiting research to postmortem and non-human animal studies. However, advances in magnetic resonance imaging (MRI) toward ultra-high magnetic field strengths of 7T and above allow visualization of laminae in living humans. One of the ultimate promises of laminar functional MRI (fMRI) is to provide information on the direction of information flow by comparing the relative contributions of different laminae to the signal within a given patch of cortex. For example, a much-sought-after laminar signature of thalamocortical connectivity is a relative signal amplitude increase in the granular layer of primary visual cortex, where the information from the eye arrives (Dumoulin et al., 2017).

However, laminar fMRI faces substantial challenges. First, human laminar fMRI does not have the spatial resolution to distinguish the six individual cortical laminae. But the resolution is sufficient to distinguish differences across cortical depth indicative of coarser scale laminar contributions. For this reason, laminar fMRI is also referred to as cortical-depth-dependent fMRI. Currently, the goal of human laminar fMRI studies is to distinguish relative granular, infragranular, and supra-granular contributions. This challenge as such is not insurmountable but a limitation that should be acknowledged.

Second, laminar fMRI is dominated by the vasculature profile, which can obscure the neural profile. fMRI detects hemodynamic consequences of neural activity. The vasculature has a specific organization across the layers: blood is supplied and collected from the surface of the cortex, and vessel diameters vary accordingly (Duvernoy et al., 1981). Consequently, hemodynamic signal amplitudes are larger at the cortical surface and systematically decrease toward deeper layers for the most commonly used fMRI contrast. Virtually all laminar fMRI studies have observed this systematic variation of signal amplitude. This systematic signal variation is related to vasculature organization not neural organization. Researchers have targeted this challenge by MRI data acquisition schemes that bias the signal to different vessel sizes (e.g., De Martino et al., 2013) or by data analyses schemes that extract other features from the fMRI signal and rely less on signal amplitude (e.g., Fracasso et al., 2016).

The third challenge of laminar fMRI is neural in origin. The differences in laminar

connectivity are related to the first synaptic contact. After the first synapse, the signal rapidly spreads across all laminae. This rapid signal transmission across the laminae is an order of magnitude faster than fMRI can measure, which can potentially completely obscure the place of entry of the signal. Similar rapid signal communication across layers prior to cortical output may obscure the laminar specificity of the cortical output. This challenge has the potential to jeopardize the entire endeavor of laminar fMRI. Besides promising new approaches pioneered in non-human animal fMRI (Yu et al., 2014), a few human neuroscience applications have been put forward suggesting that laminar fMRI is sensitive to differences across cortical depth, for example, using visual illusions (Kok et al., 2016) and population receptive field sizes (Fracasso et al., 2016).

In this issue of *Neuron*, Huber and colleagues (Huber et al., 2017) face these challenges and provide a solid demonstration of laminar fMRI to derive the direction of information flow between human cortical regions. Using a comprehensive and straightforward set of finger stimulation and movements, Huber et al. (2017) exploit the known connectivity of primary motor cortex (M1) between hemispheres, premotor and somatosensory cortex. In M1, where the granular layer is virtually absent, corticocortical and thalamocortical inputs target supra-granular layers, whereas corticospinal and corticothalamic outputs arise primarily from infragranular layers (Weiler et al., 2008). Besides using these experimental manipulations, they collected data without any stimulus or task to assess intrinsic temporal correlations of



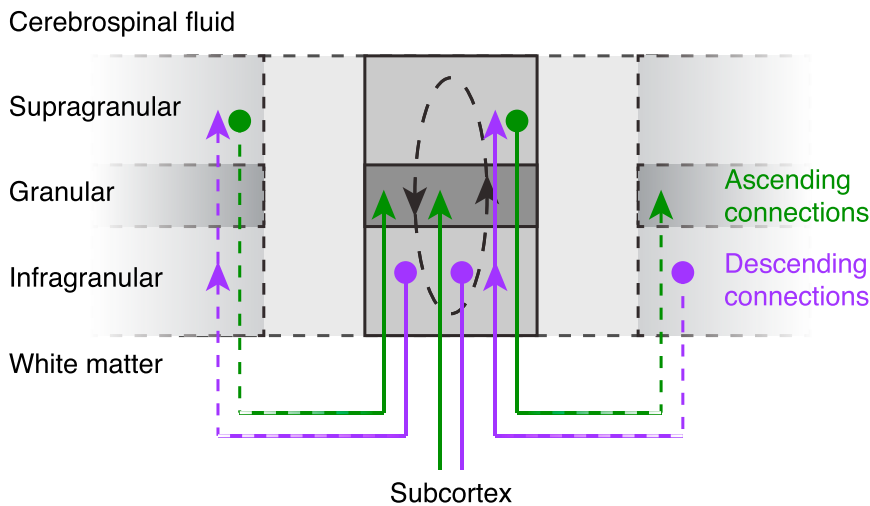


Figure 1. Schematic Summary of Laminar Connections from a Cortical Region, drawn after Shipp, 2005

the laminae between these cortical regions.

Huber et al. (2017) used an fMRI data acquisition scheme that focuses on cerebral blood volume changes (CBV-based fMRI). CBV is one specific component of the more conventional blood-oxygenation-level-dependent (BOLD) fMRI signal. Huber et al. (2017) showed higher laminar specificity for CBV-based fMRI as compared to conventional BOLD fMRI. Taking advantage of this specificity, they found evidence for somatosensory and premotor input in superficial layers of M1 and cortico-spinal motor output in deep layers. Using intrinsic laminar resting-state temporal correlations, Huber et al. (2017) showed laminar-specific functional connectivity of M1 with somatosensory and premotor areas.

Arguably, the neuroscience results of Huber et al. (2017) are not novel. Their results are expected based on the known neural architecture of M1, which Huber and colleagues confirm in living humans. However, Huber et al. (2017) provide a solid demonstration of the feasibility of

laminar fMRI, in particular, the ability of laminar fMRI to provide clues on the direction of information flow by comparing the relative contributions of different laminae within a given patch of cortex. These technical advances and feasibility demonstrations illustrate the power of human laminar fMRI and pave the way to explore other parts of cortex including those serving human cognitive abilities and those affected in clinical disorders.

fMRI approaches are easily adapted to sample many different cortical regions. Soon, these approaches will cover nearly the whole human cortex. This broad scope allows many new neuroscience questions to be answered. For example, most human and non-human approaches focus on primary sensory and motor cortex. It is an open question whether the laminar input and output principles derived from these primary cortices extend to association cortex and human cognitive functions. One working hypothesis is that there is a canonical laminar microcircuit or cortical processing unit (Dumoulin et al., 2017; Shipp, 2005). This

question goes to the heart of how the cortical circuitry is organized and operates. Ultimately, laminar fMRI provides a novel *in vivo* tool for the fields of human cognitive and clinical neuroscience with the capability to derive the direction of information flow in the human brain.

REFERENCES

- Brodman, K. (1903). Beiträge zur histologischen Lokalisation der Grosshirnrinde. II. Der Calcarinustyp. *J. Psychol. Neurol.* *11*, 133–159.
- De Martino, F., Zimmermann, J., Muckli, L., Ugurbil, K., Yacoub, E., and Goebel, R. (2013). Cortical depth dependent functional responses in humans at 7T: improved specificity with 3D GRASE. *PLoS ONE* *8*, e60514.
- Dumoulin, S.O., Fracasso, A., van der Zwaag, W., Siero, J.C.W., and Petridou, N. (2017). Ultra-high field MRI: advancing systems neuroscience towards mesoscopic human brain function. *Neuroimage*. Published online January 16, 2017. <https://doi.org/10.1016/j.neuroimage.2017.01.028>.
- Duvernoy, H.M., Delon, S., and Vannson, J.L. (1981). Cortical blood vessels of the human brain. *Brain Res. Bull.* *7*, 519–579.
- Fracasso, A., Petridou, N., and Dumoulin, S.O. (2016). Systematic variation of population receptive field properties across cortical depth in human visual cortex. *Neuroimage* *139*, 427–438.
- Huber, L., Handwerker, D.A., Jangraw, D.C., Chen, G., Hall, A., Stüber, C., Gonzalez-Castillo, J., Ivanov, D., Marrett, S., Guidi, M., et al. (2017). High-resolution CBV-fMRI allows mapping of laminar activity and connectivity of cortical input and output in human M1. *Neuron* *96*, this issue, 1253–1263.
- Kok, P., Bains, L.J., van Mourik, T., Norris, D.G., and de Lange, F.P. (2016). Selective activation of the deep layers of the human primary visual cortex by top-down feedback. *Curr. Biol.* *26*, 371–376.
- Shipp, S. (2005). The importance of being agranular: a comparative account of visual and motor cortex. *Philos. Trans. R. Soc. Lond. B Biol. Sci.* *360*, 797–814.
- Weiler, N., Wood, L., Yu, J., Solla, S.A., and Shepherd, G.M. (2008). Top-down laminar organization of the excitatory network in motor cortex. *Nat. Neurosci.* *11*, 360–366.
- Yu, X., Qian, C., Chen, D.Y., Dodd, S.J., and Koretsky, A.P. (2014). Deciphering laminar-specific neural inputs with line-scanning fMRI. *Nat. Methods* *11*, 55–58.