



Vasogenic edema versus neuroplasticity as neural correlates of hippocampal volume increase following electroconvulsive therapy

Jasper O. Nuninga^{a, b, *}, René C.W. Mandl^b, Martijn Froeling^c, Jeroen C.W. Siero^{c, d}, Metten Somers^b, Marco P. Boks^b, Wendy Nieuwdorp^b, Sophie Heringa^b, Iris E.C. Sommer^a

^a University Groningen, University Medical Center Groningen, Department of Biomedical Sciences of Cells and Systems, Groningen, the Netherlands

^b Department of Psychiatry, UMC Utrecht Brain Center, University Utrecht, Utrecht, the Netherlands

^c Department of Radiology, University Medical Center Utrecht, Utrecht, the Netherlands

^d Spinoza Centre for Neuroimaging, Amsterdam, Netherlands

ARTICLE INFO

Article history:

Received 28 February 2020

Received in revised form

7 April 2020

Accepted 27 April 2020

Available online 29 April 2020

Keywords:

electroconvulsive therapy
depression
edema
angiogenesis
perfusion
hippocampus

ABSTRACT

Background: Volume increases of the hippocampus after electroconvulsive therapy (ECT) are a robust finding, pointing into the direction of neurogenesis. However, such volumetric increases could also be explained by edema and/or neuroplastic changes (such as angiogenesis).

Objectives: If edema explains the volume increase of the hippocampus we hypothesize it would lead to increased mean diffusivity (MD). If neuroplastic would explain the volume increase, it would lead to decreased MD. To investigate angiogenesis as explanation we studied the perfusion fraction f and the pseudodiffusion component D^* obtained from intravoxel incoherent motion (IVIM) data, and relative perfusion changes obtained from arterial spin labelling (ASL) data.

Methods: Using ultra-high field (7 tesla) MRI we acquired IVIM and ASL data. We compared MD, f , D^* and ASL values for both hippocampi in 21 patients (before and after 10 ECT sessions) and 8 healthy controls (without ECT) in a linear mixed model adjusting for age and gender.

Results: We found a significant decrease in MD (which was absent in the healthy controls) in the left and right hippocampus ($t = -3.98$, $p < 0.001$). In addition, a decrease in f ($t = -4.61$, $p < 0.001$, but not in controls) and no differences in D^* or ASL perfusion values (both $p > 0.05$) were found.

Conclusions: The decrease in MD in perfusion fraction f suggest that formation of edema nor angiogenesis are responsible for the ECT-induced volume increases in the hippocampus. Also, it supports the hypothesis that hippocampal volume increases might be due to neuroplastic changes.

© 2020 The Author(s). Published by Elsevier Inc. This is an open access article under the CC BY license (<http://creativecommons.org/licenses/by/4.0/>).

Introduction

Originated in the 1930s, electroconvulsive therapy (ECT) is the most effective treatment for severe major depression [1–4], and is still widely used today to treat refractory depressive disorders. Research over the past decades focused on elucidating the mechanism by which ECT exerts its beneficial effects. These efforts, benefitting from technological advancements of studying the brain

in vivo and drawing from preclinical studies, yielded several important insights [5,6].

Compelling evidence suggest that a series of ECT treatments increases the volume of the hippocampus [7–9]. Interestingly, this increase selectively pertains to the dentate gyrus (DG) [8,10], the primary neurogenic region of the human adult brain (alongside the subventricular zone) [11,12]. The observation of DG volume increase adds to the plasticity hypothesis of the working mechanism of ECT [13,14], suggesting that neurogenesis in the DG is related to the anti-depressive effect of ECT. However, other processes could also contribute to the volume increase seen in the DG. For example, preclinical evidence suggest that plastic changes such as angiogenesis or synaptogenesis, might contribute to volume increases in

* Corresponding author. Department of Biomedical Sciences of Cells and Systems, Cognitive Neurosciences, University Medical Centre Groningen, Antonius Deusinglaan 1, 9713 AV, Groningen, the Netherlands.

E-mail address: j.o.nuninga@umcutrecht.nl (J.O. Nuninga).

the DG [15–17]. But, less beneficial processes such as the formation of edema could also contribute to volume increases.

In a previous study we used ultra-high field (7 T) magnetic resonance imaging (MRI) to measure changes in volume of the hippocampal subfields after ECT and reported a significant increase in volume exclusively for the DG [8]. To investigate whether this observed increase of DG volume could be explained by either angiogenesis or edema we now investigate the hippocampus using diffusion weighted imaging (DWI; specifically, we acquired intra-voxel incoherent motion (IVIM) data) and arterial spin labelling (ASL) in the same patient group receiving ECT. We also included a control group to assess whether changes found after ECT were due to systematic MRI scanner artifacts (such as scanner drift).

To investigate whether edema contributes to the increase in DG volume we compared the mean diffusivity (MD) of water molecules pre and post ECT. The restriction of diffusion of water molecules in the brain can be measured via diffusion weighted imaging and expressed in MD values, where low MD values reflect high restriction of water molecules (e.g. restriction due to cells, axons, dendrites etc.). In the human brain, three major types of cerebral edema can be observed: vasogenic (i.e. accumulation of extracellular fluids due to impairments of the blood-brain-barrier), cytotoxic (i.e. cell swelling due to cellular injury), and interstitial (caused by cerebrospinal fluid (CSF) entering the brain via the ependymal lining in the case of obstructive hydrocephalus) edema [18–20]. Since interstitial edema is associated to hydrocephalus, it is not expected to explain the volumetric increase in the DG/hippocampus. Vasogenic edema constitutes the accumulation of extracellular fluid, and therefore, it may be reflected as an increase in MD in the hippocampus [21]. In contrast, for cytotoxic edema a decrease in MD will be expected since the influx of extracellular fluids into the cells will cause swelling at the expense of the extracellular space [21]. However, cytotoxic edema does not result in tissue swelling (only cell swelling), since there is a redistribution of fluids from outside the cells to inside the cells and no new fluids are added to the tissue involved, making this option less likely to explain the growth in volume of the hippocampus [22]. If the increase in volume could be explained by neuroplasticity a decrease in MD will be expected since the extracellular space will be filled with newborn cells, axons, synapses, dendrites, thus decreasing the MD (i.e. diffusion will be restricted by new tissue). In the clinical and preclinical ECT literature to date, no cases of cytotoxic edema have been reported. In contrast, increased permeability of the blood brain barrier (BBB) with mild vasogenic edema has been reported as an effect of ECT [23].

To study perfusion characteristics of the hippocampus we acquired IVIM and ASL data [24,25]. The IVIM framework builds upon the observation that at low b -values (e.g. 0–200 s/mm²) the observed MR signal is not only influenced by apparent diffusion, but also by the perfusion of tissue [25,26]. Within the IVIM framework, the effects of perfusion can be disentangled from that of diffusion at low b -values, commonly resulting in two perfusion parameters: the perfusion fraction f and the pseudo diffusion component D^* [25,26]. These IVIM parameters have been shown to reflect angiogenesis and correlate with the density of microvessels in biological tissue [27]. Next to IVIM imaging, non-invasive, and more direct MRI measurements of perfusion can be obtained by arterial spin labelling (ASL). We employed IVIM and ASL in the hippocampus to see whether perfusion in the hippocampus increases after a series of ECT treatments. If ECT stimulates angiogenesis, this would lead to an increase in perfusion in the hippocampus that could potentially be measured with both IVIM and ASL.

We hypothesize that if edema takes place after ECT this will be reflected in increased MD, while a decrease in MD will reflect

restricted diffusion due to neuroplastic changes of the hippocampus including but not limited to neurogenesis (exclusively in the DG), synaptogenesis and angiogenesis. Furthermore, based on preclinical literature suggesting angiogenesis in the hippocampus after electroconvulsive seizure (ECS), we hypothesize that if angiogenesis takes place in the hippocampus, this will be reflected in an increase in perfusion.

Methods

Sample

All patients and controls were recruited at the University Medical Centre (UMC) Utrecht (The Netherlands) as part of a larger study into the effects of ECT on depression, cognition and brain measurements. For patients we used the following inclusion criteria: 1) age over 18 years, 2) a diagnosis of uni- or bipolar depression (as defined by the DSM-IV-TR [28] criteria), 3) an indication for electroconvulsive therapy (based on the Dutch guidelines for ECT). Exclusion criteria constituted: 1) treatment with ECT in previous 6 months, 2) contraindication for MRI (e.g. a pacemaker), 3) brain pathology, 4) major medical conditions (e.g. coronary heart disease), 5) pregnancy and/or lactation.

Healthy controls were included based on the demographic characteristics of the patients' sample and matched for age, sex and education. The only inclusion criterion constituted: an age over 18 years. The exclusion criteria were: 1) a (history of a) psychiatric disorder (as assessed with the MINI interview [29], Dutch version), 2) contraindication for MRI (e.g. a pacemaker), 3) other brain pathology, 4) major medical conditions (e.g. coronary heart disease), 5) pregnancy and/or lactation. Controls were included for the purpose of assessing whether brain changes found are due to systematic variations between the scan sessions (e.g. scanner drift).

Written informed consent was obtained from every participant prior to participation. The study was approved by the local Medical Ethics Board of the UMC Utrecht. In total, 38 participants were included based on the in- and exclusion criteria (26 patients, 12 controls).

ECT treatment

Electroconvulsive therapy treatment was carried out with a Thymatron IV ECT machine (bifrontotemporal electrode positioning, stimulus intensity of 150% of the titrated seizure threshold). ECT was given twice a week, for five consecutive weeks, leading up to a total of 10 ECT sessions. Patients were excluded from the analysis when they received less than 10 ECT sessions (one patient in the current study). The baseline MRI measurement was planned in the week prior to the first ECT session (usually the day before). To minimize variability, patients were scanned in the exit assessment in the week after the tenth ECT session (usually one day after the tenth session). Patients received extra ECT sessions after the exit assessment if clinically indicated.

An anaesthetic drug (etomidate/methohexital) and a muscle relaxant (succinylcholine) was administered prior to delivering the electrical current. A trained psychiatrist (or resident) delivered the electrical current while an anesthesiologist and licensed nurse monitored the patients' vital signs. An electroencephalogram was recorded from a single channel (right frontomastoid placement). A motor seizure duration of at least 20 s had to be observed for an ECT session to be considered successful (based on the Dutch guidelines on ECT [30]). If a motor seizure duration of <20s was observed, a new current was delivered with an energy increase of 5–10% (with a maximum of three attempts). For all patients, seizure duration of >20s was observed on every ECT session.

Magnetic resonance imaging acquisition

All magnetic resonance imaging (MRI) data was acquired using a 7T magnetic resonance imaging scanner (MRI; Philips Healthcare, Best, the Netherlands) with a 32-channel head coil (Nova Medical, Wilmington, MA, USA). A 3D T1-weighted TFE scan was acquired (voxel size 1 mm isotropic; TR/TE 5.5/2.04 ms; flip-angle 6°; field of view (FOV) 256 × 256 × 190; number of slices 190). Also, a 3D T2-weighted TSE scan was acquired (voxel size 0.286 × 0.286 mm² in plane resolution, 2 mm slice thickness; TR/TE 3800/60 ms; flip angle 90°; FOV 60 × 220 × 220; number of slices 30). Given that the voxel size is highly anisotropic, it is important that the FOV of the pre and post scan are placed exactly the same. To this end, we used automatic scan planning (SmartExam planning) automatically placing the FOV based on a number of anatomical characteristics of the head (extracted from a T1-weighted scan acquired before each T2-weighted scan). An IVIM scan (1.5 mm isotropic voxel size; FOV = 160 × 160 × 30; EPI factor = 55; TR/TE: 3605/60.25 ms; flip angle 90°; no gap; no cardiac gating) was acquired with 46 vol consisting of one $b = 0$ s/mm² volume and 15 b -weighted volumes (3 vol with orthogonal directions per b -value: 2, 4, 6, 8, 10, 25, 50, 75, 100, 200, 300, 400, 600, 800, 1000 s/mm²). A single slice flow sensitive alternating recovery (FAIR) ASL scan was acquired (voxel size = 1.875 × 1.875 × 3mm³; TR/TE = 1400/13.1 ms; FOV 128 × 128 × 1mm³; flip angle 90°). Additionally, an M0 image (voxel size = 1.875 × 1.875 × 3mm²; TR/TE = 2000/13.1 ms; FOV 128 × 128 × 1mm³; flip angle 90°) was acquired to internally scale the perfusion images. The purpose of including an ASL scan was solely to confirm a possible increase in perfusion in the hippocampus as measured with IVIM.

Magnetic resonance imaging processing

All data was processed using FSL, MRtrix3, ANTs, R (version 3.5.0) and MATLAB tools [31–35]. For a detailed outline of the processing of the T1-weighted and T2-weighted data and segmentation of the hippocampus please see Nuninga et al., 2019 [8]. In short, T2-weighted images were processed via the Automated Segmentation of Hippocampal Subfields (ASHS) pipeline, and ANTs tools [32,36,37]. Given that the voxel resolution of the IVIM scan is relatively large (1.5 mm, isotropic) the hippocampus was chosen as a region of interest (ROI) and not the hippocampus subfields.

IVIM datasets were preprocessed using FSL (version 5.0.9) [33] and MRtrix3 tools [34] and MATLAB [31] functions. First, the data was denoised, using *dwidenoise* [38]. Afterwards, the data was corrected for eddy currents, subject motion and bias of the main magnetic field using various FSL and MRtrix tools [33,34,39]. The IVIM model was fitted to the preprocessed data with a segmented fit (provided in the package *IVIM Model fitting* [40] for MATLAB) estimating D for all $b > 120$ s/mm². We note that for IVIM parameter estimation D was estimated at $b > 120$ s/mm², however the MD is computed from a subset of the IVIM volumes with stronger diffusion weightings ($500 \text{ s/mm}^2 < b < 1100 \text{ s/mm}^2$), which renders it sensitive to diffusion of water in the extracellular space [24,25,41]. IVIM maps were computed for the perfusion fraction f , and the pseudo diffusion component D^* . The diffusion unweighted ($b = 0$) volume was extracted from the IVIM data and registered to the T2-weighted scan using affine registration, this registration was applied consecutively to the IVIM maps [32]. The hippocampal segment yielded by ASHS (see previous paper [8]) was used as a ROI to extract the f and D^* values from the IVIM maps. These values were subsequently imported into R for statistical analyses (see ‘Statistical analyses’ below).

To assess the diffusivity characteristics of tissue in the hippocampus, the mean diffusivity (MD) was calculated at each voxel

using FSL's *dtifit* on high b -values 600–1000 s/mm² from our dataset (preprocessed as stated above; high b -values were chosen to minimize effects of perfusion influencing the MD values). Using the previously computed affine transformation the MD maps were registered to high resolution T2-space, where the hippocampal segments were available for data extraction. MD values for the hippocampus were subsequently extracted and imported into R for further analysis.

ASL datasets were processed with in-house developed functions for MATLAB. Because the only purpose of including ASL data was to see if ASL results corroborated the IVIM findings (and absolute quantification of ASL 7T FAIR data is not straightforward) no quantification of the ASL data was done. Instead, we computed the average difference between the control and the tag images (both part of the ASL scan) and divided this by the M0-image. Differences between the pre and post ECT scan reflect possible changes in perfusion. ANTs tools were used to compute the affine transformation between the M0-scan and the corresponding T2-weighted scan to register the resulting ASL maps into the space of hippocampus segments. For each subject, the hippocampus segmentation was then used to extract ASL values, which were subsequently imported into R for statistical analyses.

To check whether possible changes in perfusion or diffusion are due to overall systematic differences between the pre- and post-scan (e.g. scanner drift) an extra analysis was conducted with values from the pons as regressor in the model. To ensure that the ROI in the pons showed 100% overlap between the patients, a sphere was placed in the pons comprising of 1342 voxels on the 1 mm T1-weighted MNI152 template (available in FSL; see [supplementary figure A](#)) [33]. The T2-weighted scan was registered to the T1-scan using affine registration with ANTs [32]. The T1-weighted scan was subsequently nonlinearly registered to the 1 mm MNI152-template image [33]. The inverse of both registrations was then used to map the pons ROI back into native space. Subsequently, values for the pons were extracted and imported in R for statistical analyses.

Clinical effect

To quantify the clinical effect of ECT, the 17-item version of the Hamilton Depression Rating Scale (HAM-D) was used [42]. The HAM-D is widely used to assess the clinical effect of treatments for depression [42,43].

Statistical analyses

To assess changes in diffusion and perfusion between pre and post ECT, linear mixed models (with unstructured covariance structures) were used (p -values < 0.05 were considered significant from a two-sided test) [44]. For each parameter map (MD, f , D^* and the ASL map) separately, a linear mixed model was used with time (pre/post ECT)*type(patients/controls) as fixed effect, and age, sex as covariates and subject and hemisphere (left/right) as random factors. Subsequently, the models were (again for each parameter map separately), further split up into two models testing for controls and patients separately. If one of these latter models showed significant effects for time, the model was further split up into separate models for left and right hippocampus, to see whether the effects are driven by the left and/or right hippocampus. To examine whether the effects were specific to the hippocampus (and not due to an overall decrease in MD in the brain) and/or could be explained by the increase in volume of the hippocampus, models with significant effects for the left or right hippocampus were re-run with volumetric measurements of the hippocampus and parameter values in the pons as covariates (serving as an internal control

measure). Effect sizes (Cohen's *d*) are computed for paired observations for patients and controls separately.

For each parameter map and for the left and right hippocampus separately, repeated measures correlations [45] were computed to see if a difference over time would significantly be associated to change in depression scores (after regressing out the effects of age and sex on parameter scores and depression scores). Afterwards, a regression analysis was run with baseline values of the parameter maps (only parameters that had significant effects for time in the linear mixed model) as predictor and age, sex and baseline hippocampal volume as covariates, and difference in depression scores (baseline – exit) as dependent variable.

Results

Sample

In total, 28 participants (20 patients and 8 controls) were analyzed (totaling 44 scan sets). See Table 1 for demographics. At baseline, patients did not differ significantly from the controls in terms of age, sex, handedness and IQ (Table 1). In the patient group, the Hamilton score decreased significantly from pre to post ECT ($t = 6.55, p < 0.001$, effect size = 0.9). Due to personal reasons (two patients, four controls), anxiety in the scanner (one patient, one control), less than 10 ECT sessions (one patient) and scanning artifacts (six patients, two controls), we obtained 16 (11 patients, 5 controls) complete datasets for the IVIM measurements and 13 (10 patients, 3 controls) for the ASL measurements. However, when the data is missing completely at random linear mixed modelling is robust to missing values allowing inclusion of participants with either the baseline or exit measurement, which resulted in 28 participants (20 patients, 8 controls) for the IVIM measurements and 25 for the ASL measurements (17 patients, 8 controls). The reasons for the missing data are believed to be completely at random (e.g. scanning artifacts).

Clinical efficacy

Patients significantly improved in depression scores ($t = 6.55, p < 0.001$, effect size = 0.9). No significant correlations were found between any of the parameter maps and a change in Hamilton score (all $p > 0.05$; see Table 2). Baseline MD and *f* values were not related to the change in depressions scores using ($p > 0.05$).

Mean diffusivity, IVIM f, D, and ASL perfusion values*

The first model for mean diffusivity (MD) indicated a significant reduction for MD over time ($t = -4.005, p < 0.001$), yet no significant effect for time*group ($t = 1.533, p = 0.132$) was found. When split up for patients and controls, the model for patients indicated a significant effect for time ($t = -3.962, p < 0.001$) but not for

Table 2
Correlation coefficients parameter maps and Hamilton score.

Parameter map*	left/right	r	P
MD	left	0.581	0.061
	right	0.065	0.850
F	left	0.490	0.126
	right	-0.0001	0.999
D*	left	0.097	0.776
	right	0.086	0.798

r = repeated measures correlation coefficient; *p* = p-value; * = all *df* = 9.

controls ($t = -0.939, p = 0.359$). To see whether the effect in patients was driven by either the left or right hippocampus, the models were further split up in two separate models for left and right hippocampus. Both for the left ($t = -2.805, p = 0.012$) and right ($t = -2.219, p = 0.035$) hippocampus, significant effects for time were found (see Fig. 1). For the left hippocampus an effect size of the paired difference of 0.85 was found, and for the right hippocampus the effect size was 0.59. When including volumetric measurements of the hippocampus and MD values of the pons in the last two models, the model for the left hippocampus showed a significant effect for time ($t = -3.083, p = 0.008$). For the model of the right hippocampus, the significant effect for time disappeared ($t = -2.073, p = 0.06$).

For the *f* parameter of the IVIM fit, a significant effect for time ($t = -4.162, p < 0.001$) was found, and nonsignificant for time*group ($t = 1.901, p = 0.0621$). When the models were split up for patients and controls separately, the model for the patients indicated a significant effect for time ($t = -3.797, p < 0.001$), but not for controls ($t = -0.491, p = 0.633$). To check if the left or right hippocampus showed different effects for time, the models for patients were re-run for the left and right hippocampus separately. The left hippocampus ($t = -3.520, p = 0.002$) indicated a significant effect for time, whereas the right hippocampus did not ($t = -1.871, p = 0.079$; see Figure 1). For the left and right hippocampus effect sizes for the paired difference between pre and post ECT of 0.92 and 0.53 were found, respectively. Including volumetric measurements of the hippocampus and the *f* values for the pons in the model, the effect for time in the left hippocampus ($t = -5.147, p < 0.001$) remained significant, whereas the effect for time in the right hippocampus changed to significant ($t = -2.818, p = 0.0125$).

The first model for the D* parameter of the IVIM fit indicated no significant effect for time ($t = -0.817, p = 0.416$), yet a significant effect for time*group was found ($t = 2.295, p = 0.024$). To see if the effects for time in either the patient or control group was significant, the models were split up for each of these groups separately. Neither the patients ($t = -1.343, p = 0.186$) or the controls ($t = 1.619, p = 0.121$) showed significant effects for time.

The first model for the ASL maps indicated no significant effects for time ($t = -0.442, p = 0.662$), nor group*time effects ($t = 0.142,$

Table 1
Demographics of the sample.

Variable	Patients	Controls	diff	Statistic(test)	<i>p</i>	
Total N	21	8	–	–	–	
Age	48.9	49.25	0.33	0.05 (<i>t</i>)	0.96	
Gender	Female	5	–	.54 (χ^2)	0.46	
	Male	3				
IQ*	106.8	109.17	2.37	0.50 (<i>t</i>)	0.62	
Handedness*	left	0	–	Fisher's exact	1	
	right	5				
	Baseline (mean, SD)	Exit (mean, SD)		<i>t</i> (<i>df</i>)†	<i>p</i>	ES‡
HAM-D	21.8(6.47)	15.25(7.56)		6.55 (19)	<0.001	0.9

**n* = 26 χ^2 = chi-square test statistic; diff = difference; N = number; IQ = intelligence quotient; *p* = p-value; † = paired *t*-test; ‡ = effect size *d* for paired observations.

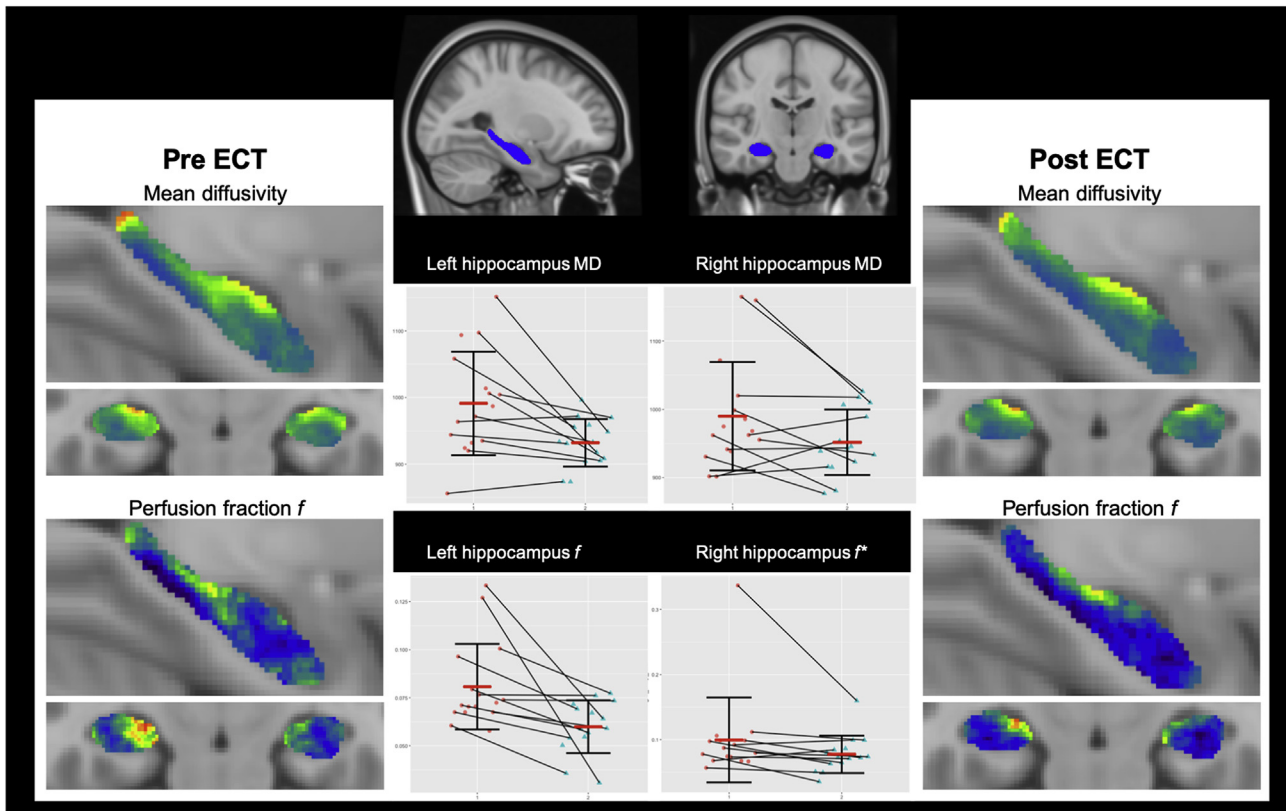


Fig. 1. Perfusion fraction f and mean diffusivity in the hippocampus, pre and post ECT.

This figure shows individual data points (red horizontal bar indicates averages) of MD and perfusion fraction f in the left and right hippocampus, before (red dot) and after ECT (blue triangle) for patients. Panel A shows the location of the hippocampus in the MNI152 1 mm template. Panel B shows the averages for the MD and f before ECT. Panel C shows the averages of MD and f after ECT. The colour scale shows low values as blue colours and high values in red. The plots show individual datapoints with standard deviation (black error bar) and average (red horizontal bar). All averages differ significantly except for right f^* = $p > 0.05$; ECT = electroconvulsive therapy; MD = mean diffusivity. (For interpretation of the references to colour in this figure legend, the reader is referred to the Web version of this article.)

$p = 0.888$). When split up for patients and controls, no significant effects for time were found ($t = -0.332$, $p = 0.734$; $t = 0.061$, $p = 0.963$; see supplementary B for bar plots of the estimated marginal means).

Discussion

Using high field magnetic resonance imaging we investigated the effect of ECT on parameters of diffusivity and perfusion in the hippocampus. We found that a series of 10 ECT sessions significantly decreased MD in both the left and the right hippocampus. This effect could not be explained by a general decrease in MD nor by the volume increase of the hippocampus for the left hippocampus. In addition, the IVIM perfusion fraction f in the left hippocampus significantly decreased after ECT (and could not be explained by a general decrease in f or by a volume increase in the hippocampus), whereas f in the right hippocampus did not significantly decrease. However, after adjusting for f values in the pons and the increase in volume in the right hippocampus (making sure that the effects found were not due overall decreases in MD, see methods), the perfusion did significantly decrease in the right hippocampus after ECT. The pseudo-diffusion component D^* did not change significantly over time, nor did the ASL perfusion values.

The decrease in MD, which is in line with recent studies looking into the effects of ECT on DTI measurements [46,47], indicates that the formation of edema is a very unlikely explanation for the volumetric increase in the hippocampus. As vasogenic edema would increase the water content in the extracellular space, this

could be reflected in an increase in MD or at least a no detectable change in MD (depending on the sensitivity of the IVIM framework and IVIM scan), as opposed to a decrease in MD. Cytotoxic edema, in contrast, could be reflected by a decrease in MD, since water of the extracellular space traverses to the intracellular space restricting diffusion in the extracellular space. However, since water of the extracellular space moves into the intracellular space, and thus reflects a redistribution of the water content, tissue swelling does not occur [22], making it therefore highly unlikely that cytotoxic edema explains the volume increase of the hippocampus.

An explanation of the decrease in MD could be that the extracellular space in the hippocampus becomes more occupied (e.g. due to neurogenesis in the DG, or the formation of synapses and axons in the other subfields of the hippocampus), leaving less space for free water diffusion. Indeed, it has been shown that the diffusion decreases when the cell density of tissue increases [48]. Interestingly, in animal models of ECT (ECS) widespread neuroplastic changes have been observed in the hippocampus. For example, dendritic spine formation, maturation and branching, mossy fiber sprouting, synaptogenesis and even gliogenesis have been observed after ECS [17,49–56]. It can be expected that all of these processes would take up the extracellular space in the hippocampus, thereby restricting diffusion and leading to the observed decrease in MD.

Animal research has also shown that ECS is capable of inducing angiogenesis in the hippocampus [15,16,57]. However, in the current study we did not find evidence of angiogenesis in the hippocampus after ECT. Instead, we found a decrease in perfusion

fraction f and no change in D^* and ASL perfusion values. The perfusion fraction f can be interpreted to reflect the volume of blood flowing into the capillaries [24,25,27]. In addition, the perfusion fraction f has been shown to correlate with microvessel density, an important marker for angiogenesis [27]. Therefore, observing a decrease in f does not suggest an increase in angiogenesis in the hippocampus after ECT. It could be, however, that the relative density of microvessels declines due to the fact that the absolute amount of microvessels remains the same yet the volume increases, therefore decreasing the fraction of microvessels. However, as this is highly speculative, future research replicating our finding of decreased perfusion fraction f while subsequently investigating the biological basis of this decline is warranted. In the current study we report no CBF changes in the hippocampus, as measured by ASL. Recently, however, several studies showed CBF increases in the hippocampus after ECT [58,59]. Moreover, these changes seemed to precede grey matter structural changes [58]. Our results are not in line with these studies. However, as noted below, the absence of an effect could indicate that our ASL data was underpowered. Future studies remain, therefore, warranted to investigate the link between structural and functional plasticity in the hippocampus.

Our study has several limitations. First, the sample size is small resulting in possible type II errors. We note, however, that we were able to detect significant decreases in MD showing that power to detect changes was sufficient and effectively ruling out increases in MD. However, the current study remains preliminary and replication with larger datasets is needed to confirm the current results. Additionally, we have not corrected the results for multiple comparisons in order to be sensitive enough to pick up effects in the current small sample. However, this might introduce Type I errors. Therefore, we have, using the Benjamini-Hochberg procedure [60] corrected the p-values reported in the manuscript. The results indicate that only the effect of ECT for the MD values in the right hippocampus did not survive multiple comparisons correction. The other effects remained significant (FDR corrected $p < 0.05$). Another limitation is that we only acquired a single slice for the ASL measurements resulting in that we could only image a section of the hippocampus. Consequently, we could have missed perfusion effects, possibly explaining why we did find a decrease in perfusion fraction f from the IVIM data with a larger coverage but not in the ASL measurements (albeit that IVIM and ASL do not necessarily need to correlate). Another restriction is the limited resolution of the IVIM data (i.e. 1.5 mm isotropic voxel size). Therefore, we could not adequately investigate subfields of the hippocampus. Investigating the subfields of the hippocampus could be an interesting focus of future research since our previous work showed a significant volume increase solely in the dentate gyrus of the hippocampus. In addition, we are unable to directly study cytotoxic edema. Although it is not likely that cytotoxic edema explains volume increases, definitively ruling out this process is not possible. Lastly, because patients were scanned after exactly ten ECT sessions in order to minimize variability introduced by differences in numbers of ECT sessions, we were not able to investigate the association of remission and hippocampal changes. Future studies could focus on studying which effects of ECT are necessary for remission.

In conclusion, we studied the effects of ECT on diffusion and perfusion related measurements by using ultra high field (7T) MRI in patients with severe depression. We found a significant decrease in MD and perfusion fraction f after a series of 10 ECT sessions. This decrease was not present in healthy controls nor in ASL perfusion values or the pseudo-diffusion component D^* . There were no correlations between any of the parameters studied and decreased depression severity. These findings question the notion that ECT

induces vasogenic edema or strong angiogenesis in the hippocampus, and strengthen our previous suggestion that neuroplastic changes are responsible for the previously reported volumetric increase of the hippocampus DG.

Declaration of competing interest

None.

CRediT authorship contribution statement

Jasper O. Nuninga: Formal analysis, Writing - original draft, Investigation, Conceptualization, Methodology, Visualization. **René C.W. Mandl:** Conceptualization, Data curation, Methodology, Software, Validation, Resources, Writing - original draft, Visualization, Formal analysis. **Martijn Froeling:** Data curation, Writing - review & editing, Methodology, Validation, Software. **Jeroen C.W. Siero:** Data curation, Writing - review & editing, Methodology, Validation, Software. **Metten Somers:** Conceptualization, Investigation, Resources, Project administration, Writing - review & editing. **Marco P. Boks:** Conceptualization, Investigation, Resources, Project administration, Writing - review & editing. **Wendy Nieuwdorp:** Investigation, Resources, Project administration, Conceptualization, Writing - review & editing. **Sophie Heringa:** Conceptualization, Investigation, Resources, Project administration. **Iris E.C. Sommer:** Conceptualization, Supervision, Resources, Funding acquisition, Methodology, Writing - original draft.

Acknowledgements

We would like to thank The Netherlands Organization for Scientific Research (NWO) for awarding Prof. Sommer the Aspasia grant. Also, we would to thank Dr. H. Kampinga for his insight and feedback on our manuscript.

Appendix A. Supplementary data

Supplementary data to this article can be found online at <https://doi.org/10.1016/j.brs.2020.04.017>.

References

- [1] UK ECT Review Group. Efficacy and safety of electroconvulsive therapy in depressive disorders: a systematic review and meta-analysis. *Lancet* 2003;361:799–808. [https://doi.org/10.1016/S0140-6736\(03\)12705-5](https://doi.org/10.1016/S0140-6736(03)12705-5).
- [2] Dierckx B, Heijnen WT, van den Broek WW, Birkenhäger TK. Efficacy of electroconvulsive therapy in bipolar versus unipolar major depression: a meta-analysis. *Bipolar Disord* 2012;14:146–50. <https://doi.org/10.1111/j.1399-5618.2012.00997.x>.
- [3] Pagnin D, de Queiroz V, Pini S, Cassano GB. Efficacy of ECT in depression: a meta-analytic review. *J ECT* 2004;20:13–20.
- [4] Kellner CH, Kaicher DC, Banerjee H, Knapp RG, Shapiro RJ, Briggs MC, et al. Depression severity in electroconvulsive therapy (ECT) versus pharmacotherapy trials. *J ECT* 2015;31:31–3. <https://doi.org/10.1097/YCT.000000000000135>.
- [5] Gbyl K, Videbech P. Electroconvulsive therapy increases brain volume in major depression: a systematic review and meta-analysis. *Acta Psychiatr Scand* 2018. <https://doi.org/10.1111/acps.12884>.
- [6] Payne NA, Prudic J. Electroconvulsive therapy: Part II: a biopsychosocial perspective. *J Psychiatr Pract* 2009;15:369–90. <https://doi.org/10.1097/01.pra.0000361278.73092.85>.
- [7] Oltegal L, Narr KL, Abbott C, Anand A, Argyelan M, Bartsch H, et al. Volume of the human hippocampus and clinical response following electroconvulsive therapy. *Biol Psychiatr* 2018. <https://doi.org/10.1016/j.biopsych.2018.05.017>.
- [8] Nuninga JO, Mandl RCW, Boks MP, Bakker S, Somers M, Heringa SM, et al. Volume increase in the dentate gyrus after electroconvulsive therapy in depressed patients as measured with 7T. *Mol Psychiatr* 2019. <https://doi.org/10.1038/s41380-019-0392-6>.
- [9] Takamiya A, Chung JK, Liang K, Graff-Guerrero A, Mimura M, Kishimoto T. Effect of electroconvulsive therapy on hippocampal and amygdala volumes: systematic review and meta-analysis. *Br J Psychiatry* 2018;212:19–26. <https://doi.org/10.1192/bjp.2017.111>.

- [10] Takamiya A, Nuninga JO, Mandl RCW, Sommer IEC, Mimura M, Kishimoto T. Volume increase of the Dentate Gyrus induced by electroconvulsive therapy: shedding light on the clinical relevance of plasticity in the hippocampus. *J ECT* 2019.
- [11] Ming G, Song H. Adult neurogenesis in the mammalian brain: significant answers and significant questions. *Neuron* 2011;70:687–702. <https://doi.org/10.1016/j.neuron.2011.05.001>.
- [12] Toda T, Parylak SL, Linker SB, Gage FH. The role of adult hippocampal neurogenesis in brain health and disease. *Mol Psychiatr* 2018. <https://doi.org/10.1038/s41380-018-0036-2>.
- [13] Bouckaert F, Sienaert P, Obbels J, Dols A, Vandenbulcke M, Stek M, et al. ECT: its brain enabling effects: a review of electroconvulsive therapy-induced structural brain plasticity. *J ECT* 2014;30:143–51. <https://doi.org/10.1097/YCT.0000000000000129>.
- [14] Koch SBJ, Morey RA, Roelofs K. The role of the dentate gyrus in stress-related disorders. *Mol Psychiatr* 2019. <https://doi.org/10.1038/s41380-019-0572-4>.
- [15] Newton SS, Girenti MJ, Collier EF, Duman RS. Electroconvulsive seizure increases adult hippocampal angiogenesis in rats. *Eur J Neurosci* 2006;24:819–28. <https://doi.org/10.1111/j.1460-9568.2006.04958.x>.
- [16] Hellsten J, West MJ, Arvidsson A, Ekstrand J, Jansson L, Wennström M, et al. Electroconvulsive seizures induce angiogenesis in adult rat Hippocampus. *Biol Psychiatr* 2005;58:871–8. <https://doi.org/10.1016/j.biopsych.2005.05.023>.
- [17] Chen F, Madsen TM, Wegener G, Nyengaard JR. Repeated electroconvulsive seizures increase the total number of synapses in adult male rat hippocampus. *Eur Neuropsychopharmacol* 2009;19:329–38. <https://doi.org/10.1016/j.euroneuro.2008.12.007>.
- [18] Qureshi AI, Suarez JL. Use of hypertonic saline solutions in treatment of cerebral edema and intracranial hypertension. *Crit Care Med* 2000;28:3301–13. <https://doi.org/10.1097/00003246-200009000-00032>.
- [19] Unterberg AW, Stover J, Kress B, Kiening KL. Edema and brain trauma. *Neuroscience* 2004;129:1019–27. <https://doi.org/10.1016/j.neuroscience.2004.06.046>.
- [20] Ho M-L, Rojas R, Eisenberg RL. Cerebral edema. *Am J Roentgenol* 2012;199:W258–73. <https://doi.org/10.2214/AJR.11.8081>.
- [21] Barzó P, Marmarou A, Fatouros P, Hayasaki K, Corwin F. Contribution of vasogenic and cellular edema to traumatic brain swelling measured by diffusion-weighted imaging. *J Neurosurg* 1997;87:900–7. <https://doi.org/10.3171/jns.1997.87.6.0900>.
- [22] Stokum JA, Gerzanich V, Simard JM. Molecular pathophysiology of cerebral edema. *J Cerebr Blood Flow Metabol* 2016;36:513–38. <https://doi.org/10.1177/0271678X15617172>.
- [23] Andrade C, Bolwig TG. Electroconvulsive therapy, hypertensive surge, blood-brain barrier breach, and amnesia. *J ECT* 2014;30:160–4. <https://doi.org/10.1097/YCT.0000000000000133>.
- [24] Le Bihan D, Breton E, Lallemand D, Aubin ML, Vignaud J, Laval-Jeantet M. Separation of diffusion and perfusion in intravoxel incoherent motion MR imaging. *Radiology* 1988;168:497–505. <https://doi.org/10.1148/radiology.168.2.3393671>.
- [25] Le Bihan D. What can we see with IVIM MRI? *Neuroimage* 2017. <https://doi.org/10.1016/j.neuroimage.2017.12.062>.
- [26] Paschoal AM, Leoni RF, dos Santos AC, Paiva FF. Intravoxel incoherent motion MRI in neurological and cerebrovascular diseases. *NeuroImage Clin* 2018;20:705–14. <https://doi.org/10.1016/j.nicl.2018.08.030>.
- [27] Lee H-J, Rha SY, Chung YE, Shim HS, Kim YJ, Hur J, et al. Tumor perfusion-related parameter of diffusion-weighted magnetic resonance imaging: correlation with histological microvessel density. *Magn Reson Med* 2014;71:1554–8. <https://doi.org/10.1002/mrm.24810>.
- [28] Diagnostic and statistical manual of mental disorders. In: Text revision (DSM-IV-TR), fourth ed., vol. 1. Arlington, VA: American Psychiatric Association; 2000. <https://doi.org/10.1176/appi.books.9780890423349>.
- [29] van Vliet IM, de Beurs E. The MINI-International Neuropsychiatric Interview. A brief structured diagnostic psychiatric interview for DSM-IV & ICD-10 psychiatric disorders. *Tijdschr Psychiatr* 2007;49:393–7.
- [30] Broek WW Van Den, Birkenhäger T, Boer D de, Burggraaf J. Richtlijn elektroconvulsivetherapie. *Ned Ver Voor Psychiatr* 2010;1–36.
- [31] MATLAB R2017b 2017.
- [32] Avants BB, Tustison NJ, Song G, Cook PA, Klein A, Gee JC. A reproducible evaluation of ANTs similarity metric performance in brain image registration. *Neuroimage* 2011;54:2033–44. <https://doi.org/10.1016/j.neuroimage.2010.09.025>.
- [33] Smith SM, Jenkinson M, Woolrich MW, Beckmann CF, Behrens TEJ, Johansen-Berg H, et al. Advances in functional and structural MR image analysis and implementation as FSL. *Neuroimage* 2004;23(Suppl 1):S208–19. <https://doi.org/10.1016/j.neuroimage.2004.07.051>.
- [34] Tournier J-D, Calamante F, Connelly A. MRtrix: diffusion tractography in crossing fiber regions. *Int J Imag Syst Technol* 2012;22:53–66. <https://doi.org/10.1002/ima.22005>.
- [35] R Core Team. R. A language and environment for statistical computing. 2013.
- [36] Yushkevich PA, Pluta JB, Wang H, Xie L, Ding S-L, Gertje EC, et al. Automated volumetry and regional thickness analysis of hippocampal subfields and medial temporal cortical structures in mild cognitive impairment. *Hum Brain Mapp* 2015;36:258–87. <https://doi.org/10.1002/hbm.22627>.
- [37] Wisse LEM, Kuijff HJ, Honingh AM, Wang H, Pluta JB, Das SR, et al. Automated hippocampal subfield segmentation at 7T MRI. *AJNR (Am J Neuroradiol)* 2016;37:1050–7. <https://doi.org/10.3174/ajnr.A4659>.
- [38] Veraart J, Fieremans E, Novikov DS. Diffusion MRI noise mapping using random matrix theory. *Magn Reson Med* 2016;76:1582–93. <https://doi.org/10.1002/mrm.26059>.
- [39] Andersson JLR, Sotiropoulos SN. An integrated approach to correction for off-resonance effects and subject movement in diffusion MR imaging. *Neuroimage* 2015;125:1063–78. <https://doi.org/10.1016/j.neuroimage.2015.10.019>.
- [40] Jalnefjord O, Andersson M, Montelius M, Starck G, Elf A-K, Johanson V, et al. Comparison of methods for estimation of the intravoxel incoherent motion (IVIM) diffusion coefficient (D) and perfusion fraction (f). *Magn Reson Mater Phys Biol Med* 2018;31:715–23. <https://doi.org/10.1007/s10334-018-0697-5>.
- [41] Fornasa F. Diffusion-weighted magnetic resonance imaging: what makes water run fast or slow? *J Clin Imag Sci* 2011;1:27. <https://doi.org/10.4103/2156-7514.81294>.
- [42] Hamilton M. A rating scale for depression. *J Neurol Neurosurg Psychiatry* 1960;23:56–62. <https://doi.org/10.1136/jnnp.23.1.56>.
- [43] Moran PW, Lambert MJ. A review of current assessment tools for monitoring changes in depression. In: Lambert MS, Christensen ER, DeJulio SS, editors. *Assess. Psychother. outcome*; 1983. New York, NY, NY.
- [44] Bates D, Mächler M, Bolker B, Walker S. Fitting linear mixed-effects models using lme4. *J Stat Software* 2015;67. <https://doi.org/10.18637/jss.v067.i01>.
- [45] Bakdash JZ, Marusich LR. Repeated measures correlation. *Front Psychol* 2017;8. <https://doi.org/10.3389/fpsyg.2017.00456>.
- [46] Yrondi A, Nemmi F, Billoux S, Giron A, Sporer M, Taib S, et al. Significant decrease in Hippocampus and amygdala mean diffusivity in treatment-resistant depression patients who respond to electroconvulsive therapy. *Front Psychiatr* 2019;10. <https://doi.org/10.3389/fpsyg.2019.00694>.
- [47] Jorgensen A, Magnusson P, Hanson LG, Kirkegaard T, Benveniste H, Lee H, et al. Regional brain volumes, diffusivity, and metabolite changes after electroconvulsive therapy for severe depression. *Acta Psychiatr Scand* 2016;133:154–64. <https://doi.org/10.1111/acps.12462>.
- [48] Luo J, Zhou K, Zhang B, Luo N, Bian J. Intravoxel incoherent motion diffusion-weighted imaging for evaluation of the cell density and angiogenesis of cirrhosis-related nodules in an experimental rat model: comparison and correlation with dynamic contrast-enhanced MRI. *J Magn Reson Imag* 2019. <https://doi.org/10.1002/jmri.26845>.
- [49] Zhao C, Warner-Schmidt J, Duman R S, Gage FH. Electroconvulsive seizure promotes spine maturation in newborn dentate granule cells in adult rat. *Dev Neurobiol* 2012;72:937–42. <https://doi.org/10.1002/dneu.20986>.
- [50] Gombos Z, Spiller A, Cottrell GA, Racine RJ, McIntyre Burnham W. Mossy fiber sprouting induced by repeated electroconvulsive shock seizures. *Brain Res* 1999;844:28–33.
- [51] Lamont SR, Paulls A, Stewart CA. Repeated electroconvulsive stimulation, but not antidepressant drugs, induces mossy fibre sprouting in the rat hippocampus. *Brain Res* 2001;893:53–8.
- [52] Smitha JSM, Roopa R, Khaleel N, Kutty BM, Andrade C. Images in electroconvulsive therapy. *J ECT* 2014;30:191–2. <https://doi.org/10.1097/YCT.0000000000000077>.
- [53] Kaae SS, Chen F, Wegener G, Madsen TM, Nyengaard JR. Quantitative hippocampal structural changes following electroconvulsive seizure treatment in a rat model of depression. *Synapse* 2012;66:667–76. <https://doi.org/10.1002/syn.21553>.
- [54] Wennström M, Hellsten J, Ekdahl CT, Tingström A. Electroconvulsive seizures induce proliferation of NG2-expressing glial cells in adult rat hippocampus. *Biol Psychiatr* 2003;54:1015–24. [https://doi.org/10.1016/S0006-3223\(03\)00693-0](https://doi.org/10.1016/S0006-3223(03)00693-0).
- [55] Wennström M, Hellsten J, Ekstrand J, Lindgren H, Tingström A. Corticosterone-induced inhibition of gliogenesis in rat Hippocampus is counteracted by electroconvulsive seizures. *Biol Psychiatr* 2006;59:178–86. <https://doi.org/10.1016/j.biopsych.2005.08.032>.
- [56] Vaidya VA, Siuciak JA, Du F, Duman RS. Hippocampal mossy fiber sprouting induced by chronic electroconvulsive seizures. *Neuroscience* 1999;89:157–66. [https://doi.org/10.1016/S0306-4522\(98\)00289-9](https://doi.org/10.1016/S0306-4522(98)00289-9).
- [57] Ekstrand J, Hellsten J, Wennström M, Tingström A. Differential inhibition of neurogenesis and angiogenesis by corticosterone in rats stimulated with electroconvulsive seizures. *Prog Neuro-Psychopharmacol Biol Psychiatry* 2008;32:1466–72. <https://doi.org/10.1016/j.pnpbp.2008.05.012>.
- [58] Leaver AM, Vasavada M, Joshi SH, Wade B, Woods RP, Espinoza R, et al. Mechanisms of antidepressant response to electroconvulsive therapy studied with perfusion magnetic resonance imaging. *Biol Psychiatr* 2019;85:466–76. <https://doi.org/10.1016/j.biopsych.2018.09.021>.
- [59] Leaver AM, Vasavada M, Kubicki A, Wade B, Loureiro J, Hellemann G, et al. Hippocampal subregions and networks linked with antidepressant response to electroconvulsive therapy. *Mol Psychiatr* 2020. <https://doi.org/10.1038/s41380-020-0666-z>.
- [60] Benjamini Y, Hochberg Y. Controlling the false discovery rate: a practical and powerful approach to multiple testing. *J Roy Stat Soc* 1995;57:289–300. <https://doi.org/10.2307/2346101>.